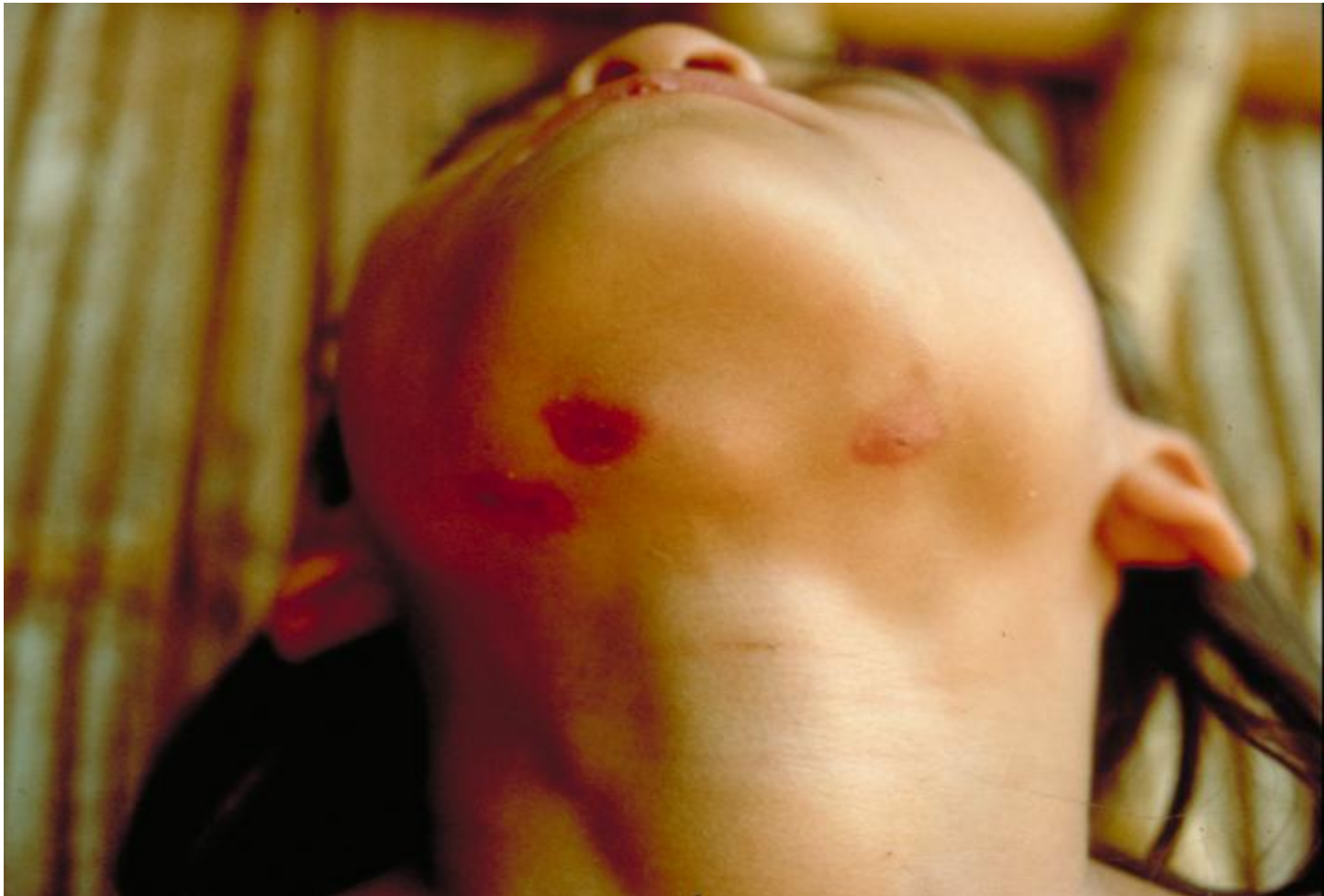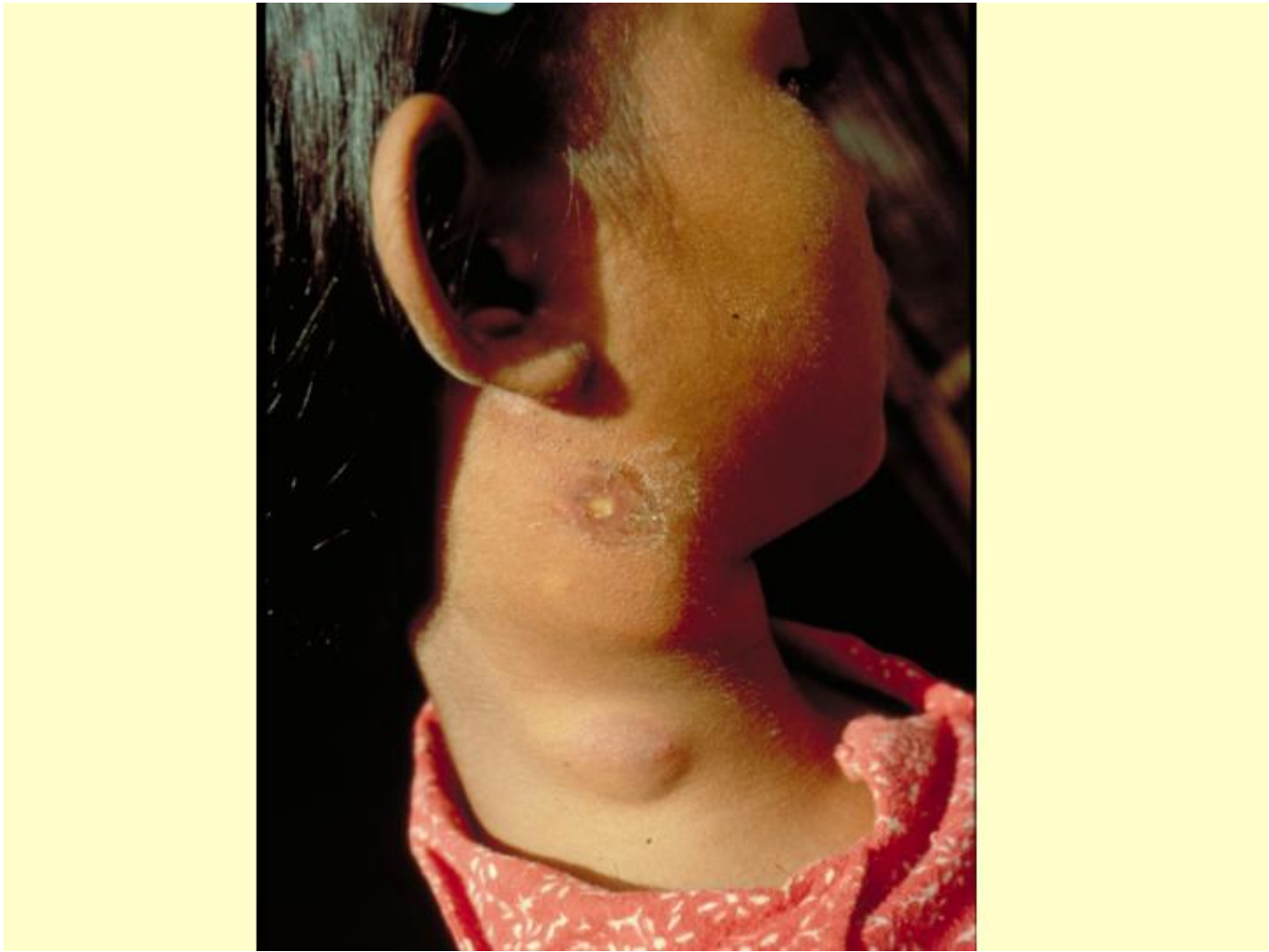

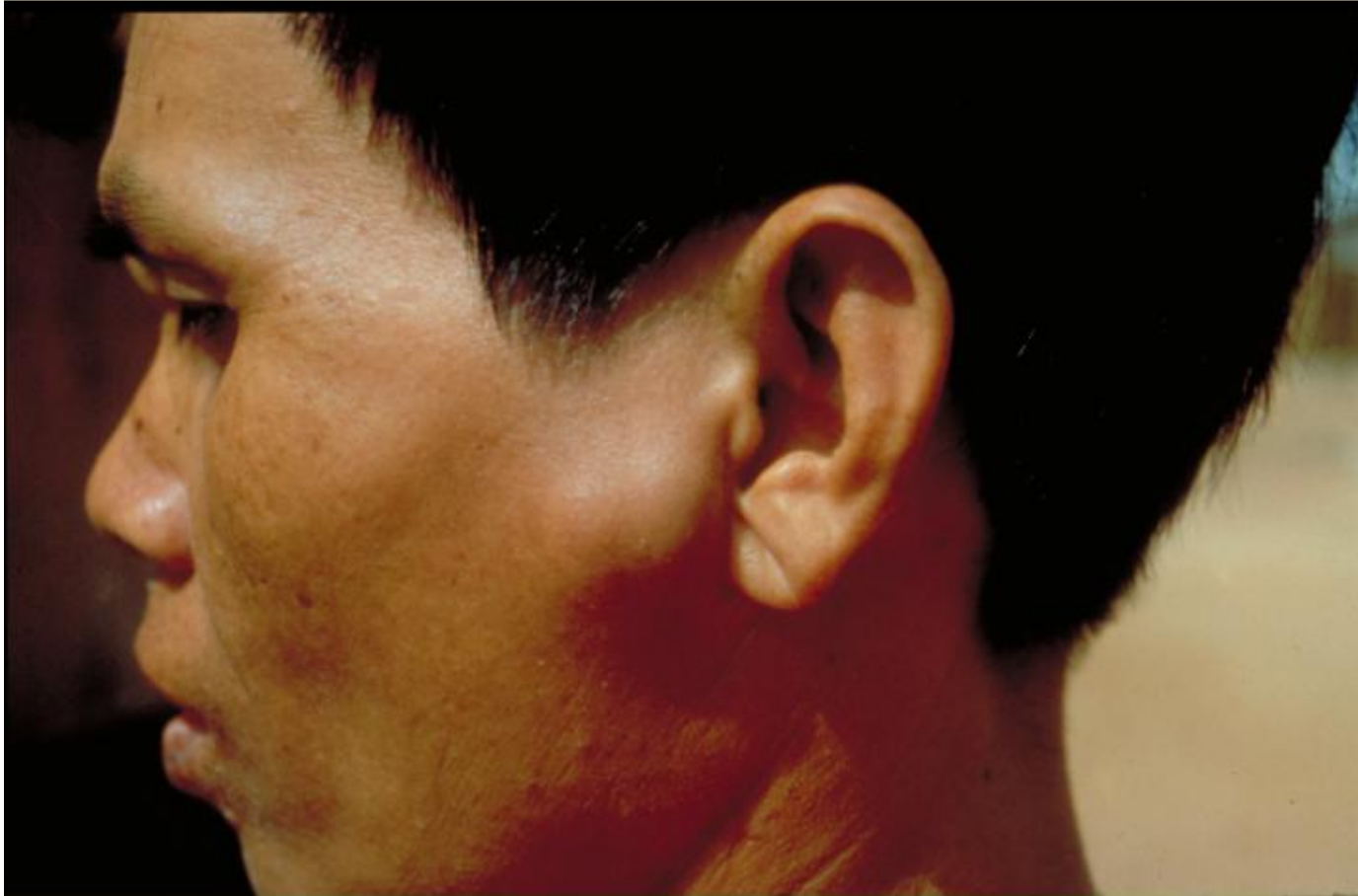
She has tuberculosis of peripheral lymph nodes. Although lymphatic tuberculosis may appear to be a localized disease process, it is not as the systemic signs and symptoms in this child indicate. At least five lesions can be seen, but it is likely that there are more less apparent ones in deeper structures.

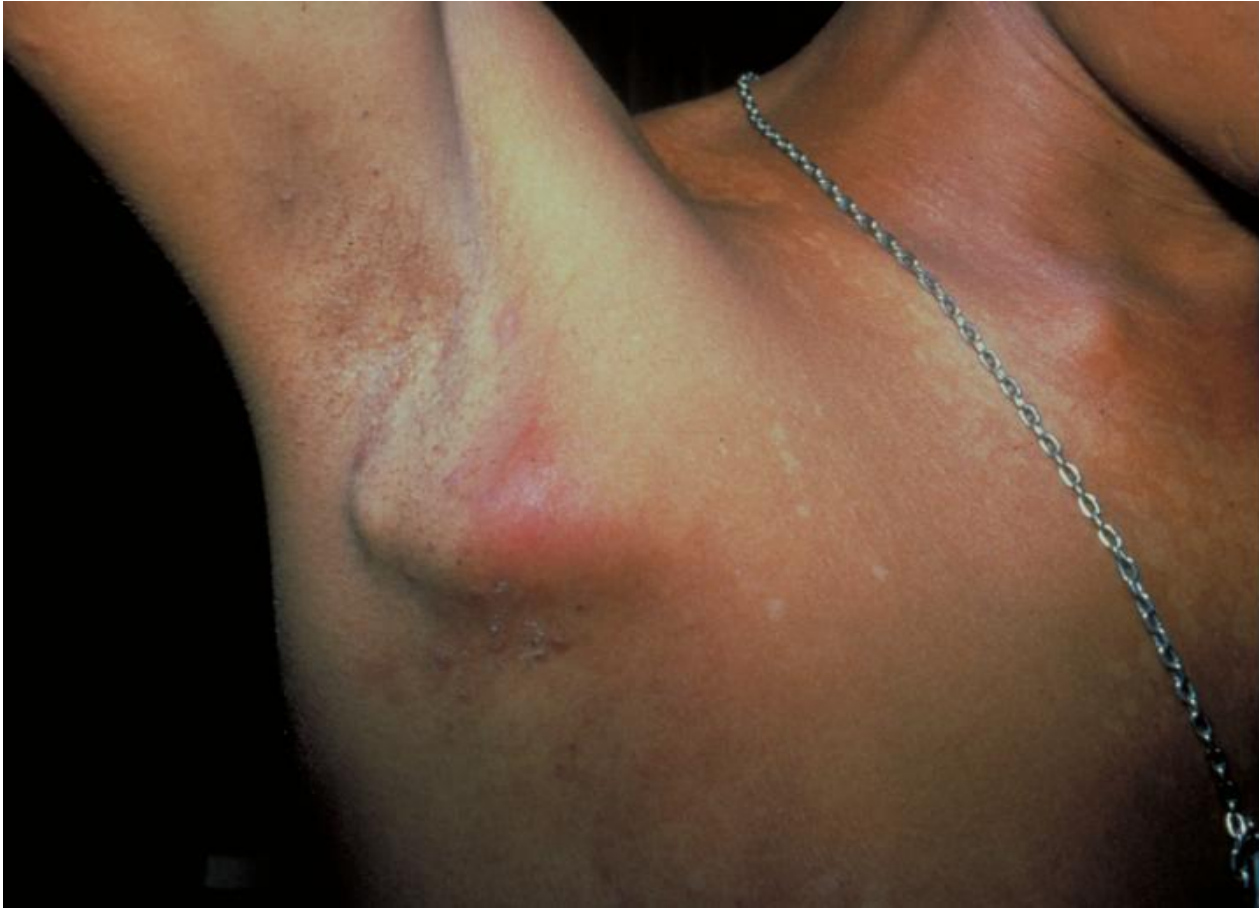



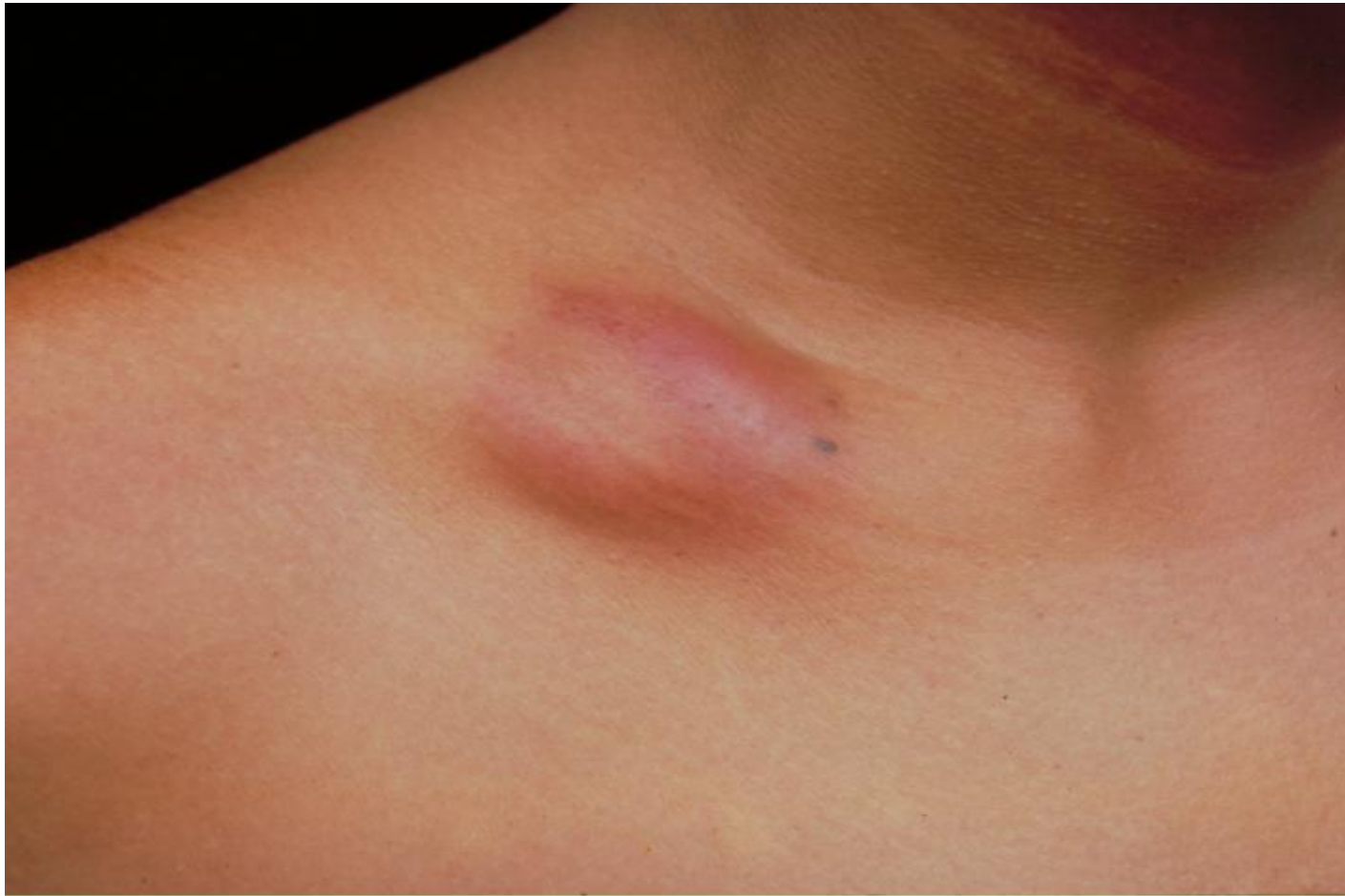This patient was referred to the tuberculosis clinic with the question of otitis media. There was no otitis. The patient had lost weight and had signs and symptoms of systemic illness. The pre-auricular lesion was cold to the touch and was apparently fluctuating. The abscess was aspirated. A Gram stain showed no organisms and careful examination of a Ziehl-Neelsen stained smear revealed acid-fast bacilli.



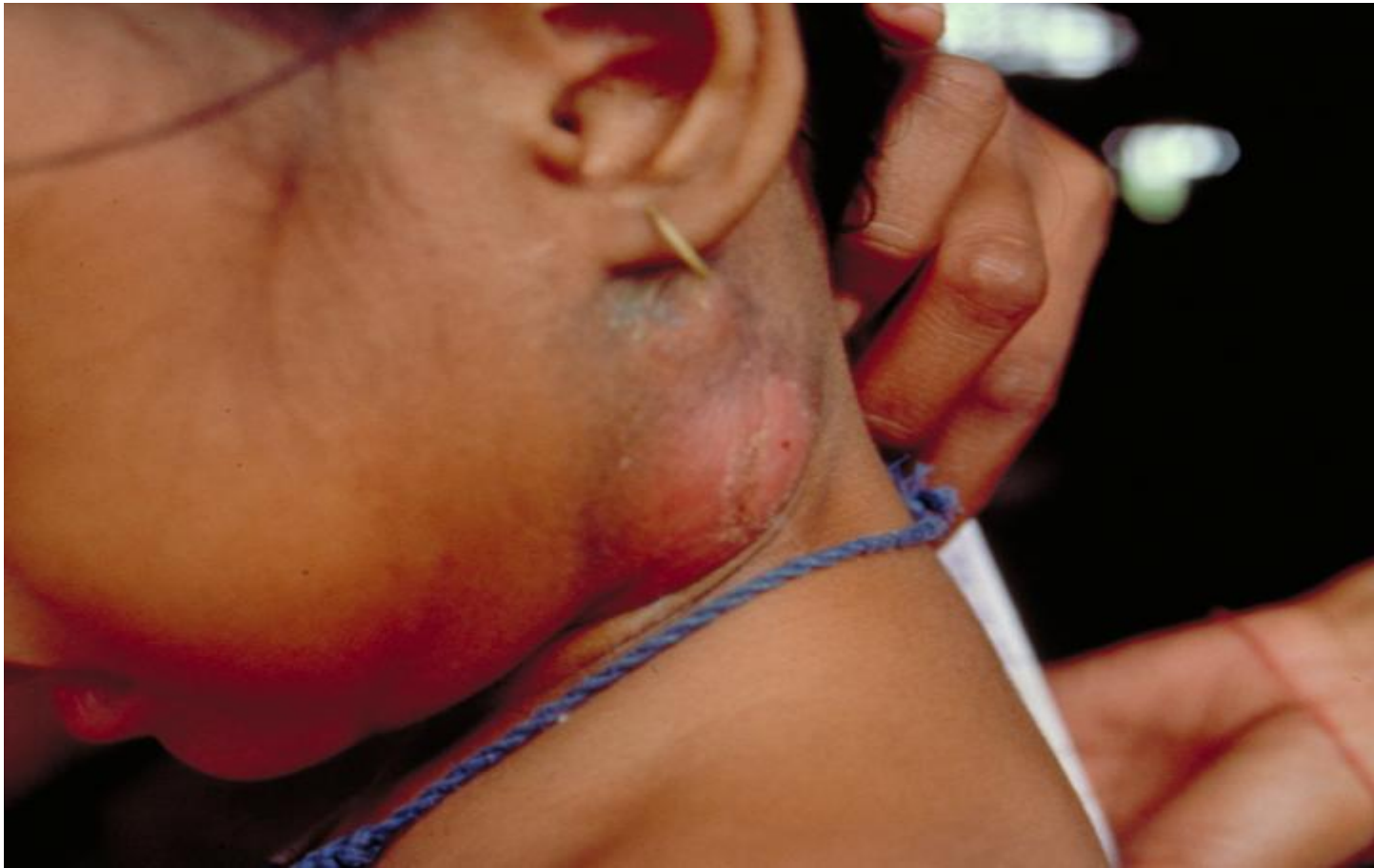While peripheral lymphatic tuberculosis is most frequently found around the neck, the axilla may also be affected. Several lymph nodes may be matted together as in this patient. Some nodes have undergone liquefaction leading to discoloration of the skin.



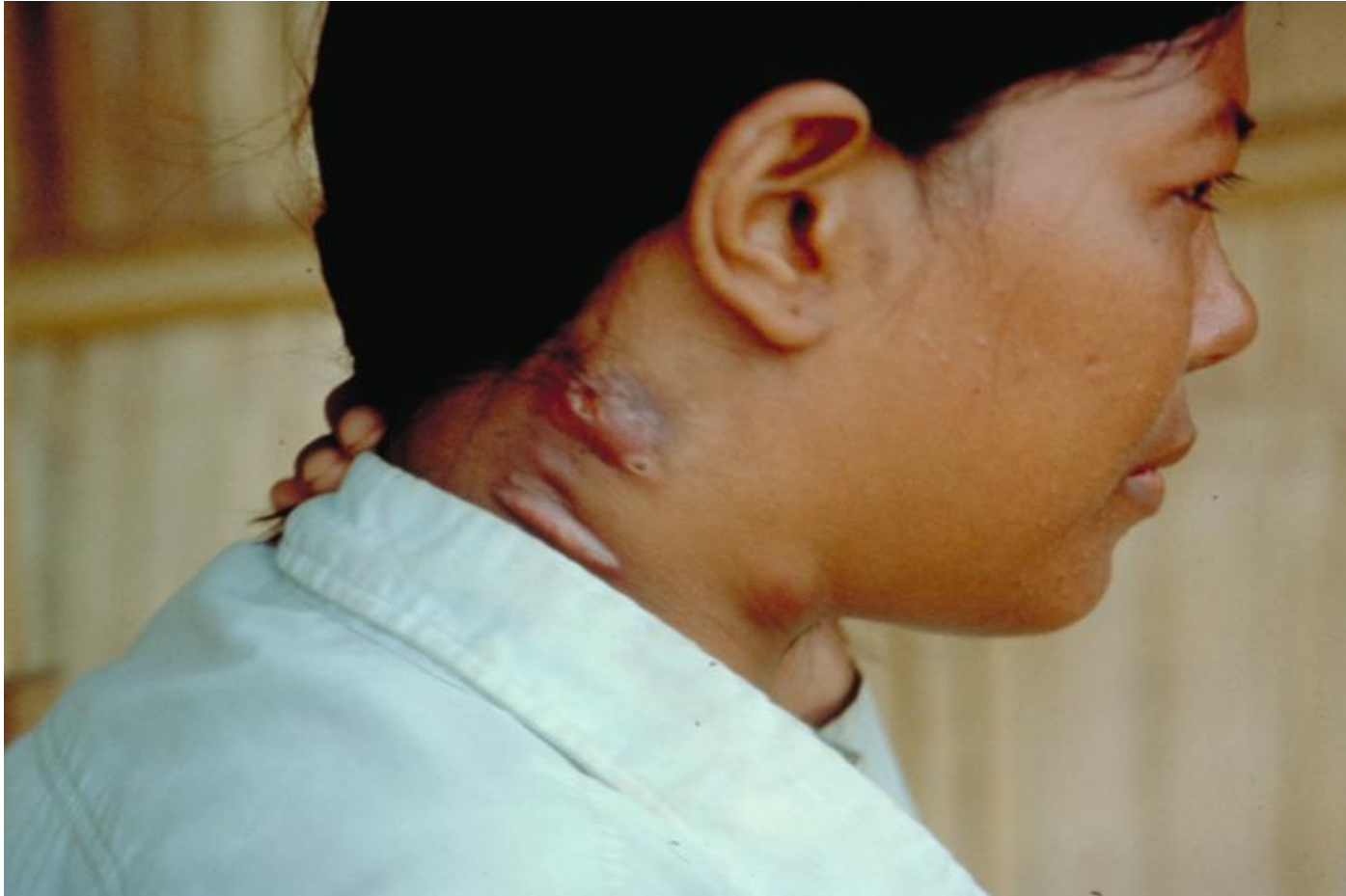In this patient, any affected lymph node in the lesion had undergone complete caseation with discoloration of the skin.



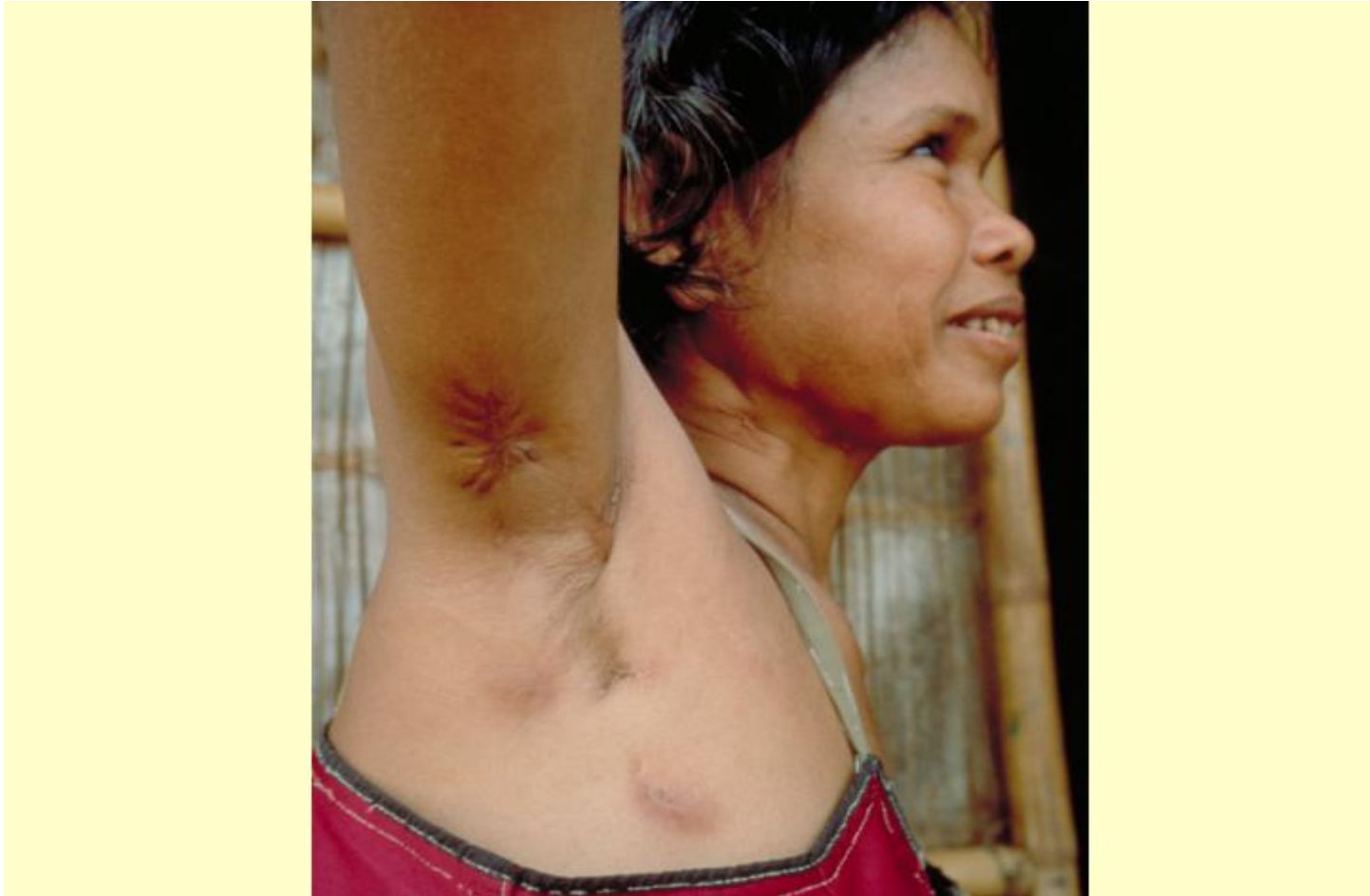This abscess was close to breaking through the skin, yet it felt cold to the touch and the child felt remarkably little pain when the lesion was touched. Such a finding should raise a high index of suspicion for tuberculosis.



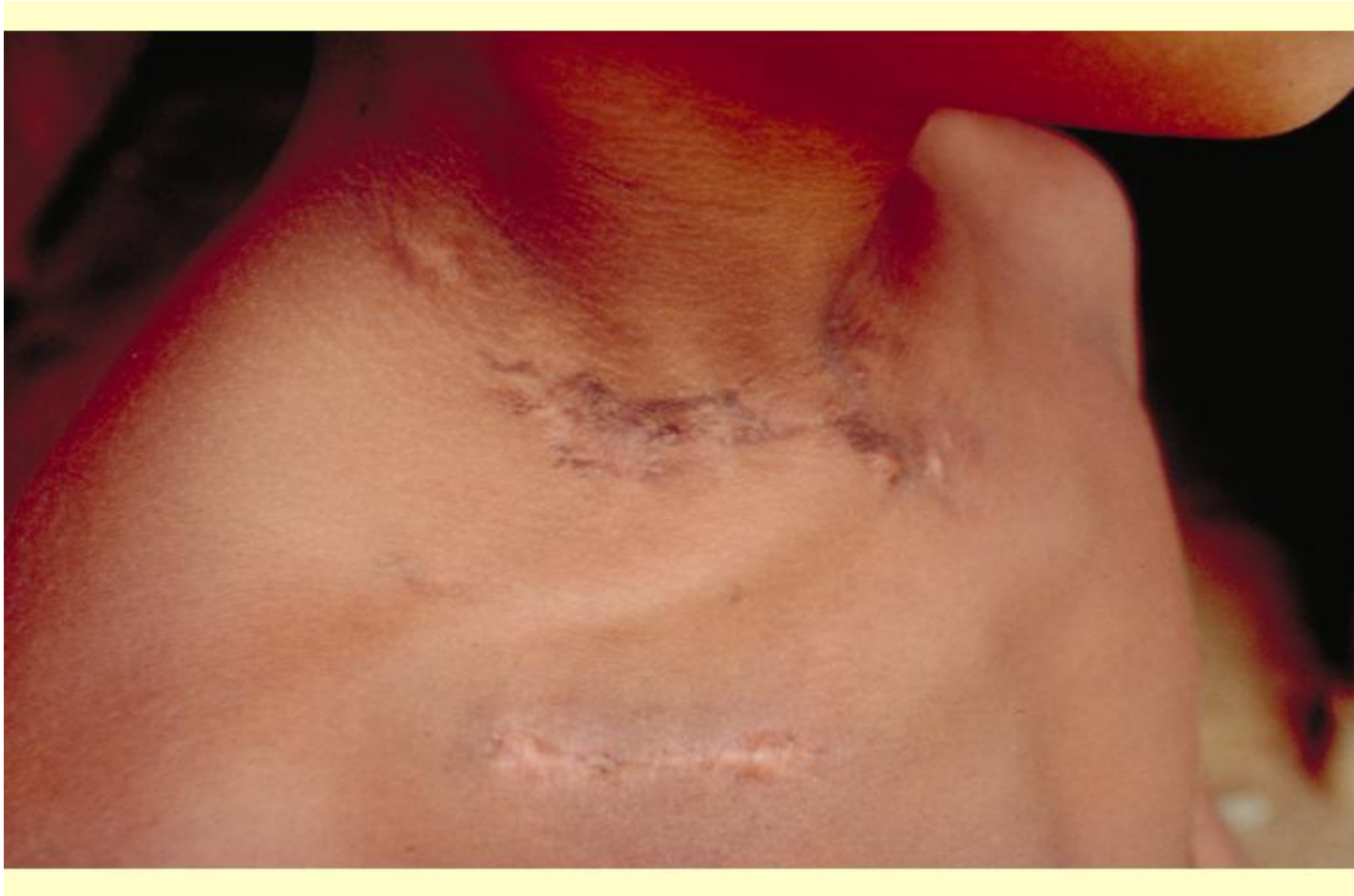This patient has chronic peripheral lymphatic tuberculosis with some lesions healed with scarring, while others are still showing activity.



This patient had a seven-year history of lymphatic tuberculosis. Many lesions have apparently healed, but some are still active (note inflammation surrounding the most caudal axillary lesion).



At first sight, all of the lesions resulting from peripheral lymphatic tuberculosis in this patient have healed. However, as the example of the previous patient demonstrates, one can never be certain. It thus may be good policy to offer curative chemotherapy to any patient with signs of tuberculosis of peripheral lymph nodes.



The patient did not only have tuberculosis of the ankle, he also had peripheral lymphatic tuberculosis, tuberculous mastitis (exceedingly rare in men), pleural thickening from past pleural tuberculosis, multiple abscesses, and had been operated for a presumable tuberculous epididymitis. While such multi-system disease in a young man should pose little difficulties in making the diagnosis of tuberculosis, it had not been taken into consideration for a prolonged period of time.

